

Jerrold Lerman, M.D., Editor

Anesthesiology 2002; 96:497-503

© 2002 American Society of Anesthesiologists, Inc. Lippincott Williams & Wilkins, Inc.

Anesthetic Management of Deep Hypothermic Circulatory Arrest for Cerebral Aneurysm Clipping

William L. Young, M.D.,* Michael T. Lawton, M.D.,† Dhanesh K. Gupta, M.D.,‡ Tomoki Hashimoto, M.D.§

ADVANCES in both neurosurgical and anesthetic techniques have considerably improved the surgical treatment of cerebral aneurysms.^{1,2} In parallel, endovascular treatment has gained progressively greater acceptance in the last 10 yr.³ However, there remains a small subset of patients in whom conventional neurosurgical approaches still carry an exceptionally high morbidity and mortality. The use of deep hypothermic circulatory arrest (DHCA) in well-selected patients offers a reasonable risk-to-benefit profile when compared with the natural history of the untreated disease.

The DHCA approach is not new.^{4,5} Renewed enthusiasm for this technique as a modality of treatment for complex cerebral aneurysms that are not amenable to traditional surgical or endovascular techniques has been fostered by recent advances in cardiopulmonary bypass technology.⁷⁻¹⁰

This article will briefly review the rationale for DHCA in the setting of cerebral aneurysm treatment. We will then use the main aspects of the protocol practiced by the senior author (WLY), as a point of departure to review the issues regarding anesthetic and perioperative management.

Rationale

The ability to temporarily eliminate or reduce blood flow into an aneurysm gives the surgeon an important advantage—without flow, an aneurysm is converted from a hard, pulsating mass into a soft, collapsed sac, allowing more aggressive manipulation of the aneurysm

to complete its dissection. With most aneurysms, temporary occlusion of the proximal parent artery or arteries will effectively control blood flow into the lesion. With large or complex aneurysms, the aneurysm mass may prevent optimal visualization and clip application to the neck. Collapse of the aneurysm mass creates more working space for dissection and precise clip application.

Deep hypothermic circulatory arrest is used for aneurysms that cannot be adequately controlled by conventional surgical or endovascular techniques. Aneurysms in the anterior circulation are, in general, accessible enough to be managed with temporary clipping. Aneurysms that defy conventional treatment are typically in the posterior circulation and large (10–25 mm in diameter) or giant (>25 mm in diameter) in size.¹¹ Often these aneurysms cannot be collapsed easily because of the breadth of the neck, the complexity of the arterial branches at the base, the presence of thrombus or endovascular coils in the lumen, arterioma or calcium in the walls, and fusiform configuration. These anatomic features make direct clipping more difficult and lower the efficacy of conventional techniques. The surgeon's ability to manage these anatomic factors is directly related to operative exposure. When proximal and distal arteries are inaccessible with these complex aneurysms, DHCA may provide the only safe and effective means of vascular control. Deep hypothermic circulatory arrest should be considered an option of last resort for these unusual aneurysms, when all conventional techniques have failed or have been carefully considered. Rarely, DHCA has also been proposed or described for other central nervous system lesions, such as tumors⁸ or arteriovenous malformations,¹² but this discussion is not within the scope of this article.

Perioperative Management Protocol

The logistics for neurosurgical DHCA require careful planning and excellent communication. There may be multiple healthcare personnel involved in the perioperative care, including but not limited to anesthesiologists, neurosurgeons, cardiac surgeons, neurologists, cardiologists, intensivists, nurses, and perfusionists.

Preoperative preparation includes assessing the power capabilities (including availability of both normal and emergency outlets) of all operating room electrical cir-

*James P. Livingston Professor and Vice-chair, Department of Anesthesia and Perioperative Care, Professor of Neurological Surgery and Neurology, and the Center for Cerebrovascular Research, † Assistant Professor, Department of Neurological Surgery and the Center for Cerebrovascular Research, ‡ Assistant Professor, Department of Anesthesia and Perioperative Care and the Center for Cerebrovascular Research, § Investigator, Center for Cerebrovascular Research, University of California, San Francisco, San Francisco, California.

Received from the Departments of Anesthesia and Perioperative Care, Neurological Surgery, and Neurology, and the Center for Cerebrovascular Research, University of California, San Francisco, San Francisco, California. Submitted for publication January 2, 2001. Accepted for publication June 7, 2001. This work was supported in part by a US Public Health Service grant, No. NINDS K2402091 (to Dr. Young).

Address reprint requests to Dr. Young: Center for Cerebrovascular Research, University of California, San Francisco, 1001 Potrero Avenue, Room 3C-38, San Francisco, CA 94110. Address electronic mail to: ccr@anesthesia.ucsf.edu. Individual article reprints may be purchased through the Journal Web site, www.anesthesiology.org.

The illustrations for this section are prepared by Dimitri Karetnikov, 7 Ten-nyson Drive, Plainsboro, New Jersey 08536.

cuits to meet the extremely large perioperative power demands required to operate all required anesthesia equipment, (the cardiopulmonary bypass machine, the neurosurgical operating microscope, and video display monitors).

Preoperative evaluation of the patient should include evaluation of cardiovascular disease that might contraindicate femoral cannulation. If significant aortic insufficiency is present, median sternotomy and left ventricular venting may be required for safe conduct of cardiopulmonary bypass (CPB).

Before induction of general anesthesia, arterial line placement is facilitated by the judicious use of local anesthetics, anxiolytics, and narcotics. Oversedation of a patient with altered sensorium from subarachnoid hemorrhage (SAH) may increase the risk of aspiration or, by affecting oxygenation and ventilation, may increase intracranial pressure. Calcium channel blockers are frequently used in the preoperative medication of patients harboring ruptured intracranial aneurysms,¹³ and some practices use them as a prophylactic measure even for unruptured lesions.¹⁴

Anesthesia is induced with an intravenous sedative-hypnotic and a relatively generous dose of narcotics (e.g., fentanyl 10–50 $\mu\text{g}/\text{kg}$). Use of benzodiazepines such as midazolam during the peri-induction period may minimize the potential for intraoperative recall. Tracheal intubation is facilitated with a nondepolarizing muscle relaxant and ventilation is adjusted to provide a Paco_2 in the 32–34 mmHg range. To minimize the risk or consequences of air embolism (either from extracorporeal circulation or neurosurgical exposure), nitrous oxide is not administered and a low-dose volatile anesthetic is titrated to maintain amnesia and hemodynamic stability. Hemodynamic management before the initiation of cardiopulmonary bypass is focused on maintaining a cerebral perfusion pressure within ± 10 –15% of the preoperative range.

For intraoperative management and monitoring, large bore peripheral intravenous access is obtained, a pulmonary artery catheter is placed, external defibrillator pads are applied, and a transesophageal echocardiography (TEE) probe and a bladder catheter are inserted. The patient is temporarily turned into the lateral position to place a spinal subarachnoid drainage system. Then, the patient is positioned to allow surgical access to the head as well as both inguinal regions and, if necessary, the chest for median sternotomy. The majority of aneurysms may be accessed by approaches that are routinely performed in the supine position (e.g., orbitozygomatic or transpetrosal approach). It is possible to perform a far-lateral craniotomy for which the head and shoulders are positioned in the “3/4 prone” position and the torso is rotated so that the groin is close to supine. Using positioning other than supine, however, might make access

to the chest for median sternotomy more difficult. (Should this become necessary). The head is locked in rigid pin fixation according to the neurosurgical approach. Temperature probes are placed against the tympanic membrane, nasopharynx, axilla, and rectum. Scalp electroencephalogram (EEG) is monitored using a 2-channel (bihemispheric) montage. Mannitol (0.5–1 g/kg) can be given for brain relaxation once the craniotomy is underway.

During craniotomy and dural opening, platelet-rich plasma and red blood cells can be harvested for postbypass reinfusion to aid in the return of normal coagulation status. Euvolemia is maintained by replacing the amount of blood withdrawn with an equal volume of albumin. A baseline kaolin activated coagulation time (ACT) is drawn to guide heparinization. After dural opening, a temperature probe (Mon-a-Therm, Mallinckrodt, St. Louis, MO) is placed directly into the exposed cortex (hemispheric cortex for carotid territory exposures or cerebellar cortex for posterior approaches).

During the period just before CPB, thiopental or propofol is titrated in small (50–100 mg) doses to achieve burst-suppression pattern on the raw EEG signal. A continuous infusion is established to maintain the EEG pattern during normothermia.¹⁵ Once cooling begins, the infusion is left constant at the normothermic rate. Alpha-stat Paco_2 management is used. During circulatory arrest, the drug infusion used for EEG burst-suppression is interrupted and then restarted at the same rate during rewarming.

The aneurysm is dissected free as much as possible during spontaneous circulation. Dissection time varies greatly depending on the surgical approach, but typically 2 or 3 h after the craniotomy begins, CPB can be established. Before cannulation, heparin 300 U/kg is administered intravenously *via* a central venous line. After intravascular mixing is complete (1–2 min), an ACT is measured to ensure adequate heparinization, with the goal of an ACT ≥ 400 sec (or three times the control value). Adequacy of muscle relaxation is confirmed and additional doses of muscle relaxant, fentanyl, and midazolam are administered to counteract the dilutional effect of CPB initiation.

After the common femoral artery and vein are cannulated by percutaneous cannulation or direct surgical cut-down, and the position of the venous cannula at the level of the right atrium is confirmed with transesophageal echocardiogram, cardiopulmonary bypass is initiated. Fluid loading and a phenylephrine infusion assist in maintaining bypass flow at $2.5 \text{ L}\cdot\text{min}^{-1}\text{m}^{-2}$ with a mean arterial pressure of approximately 50 mmHg. Once adequate flow is achieved, systemic hypothermia is induced by cooling the oxygenated blood through the extracorporeal exchanger. Once ventricular fibrillation occurs, potassium is given through the right atrial port of the pulmonary artery catheter to achieve asystole. Usually

less than three boluses of 20 mEq are necessary. When the brain temperature reaches 15°C, the circulation is arrested and blood is drained through the venous cannula until the cerebral vasculature appears relaxed. Too much drainage can result in a negative pressure gradient with the consequences of air embolism and perhaps the tearing of small fragile perforating vessels emanating from the aneurysm dome or parent vessels.

After circulatory arrest, aneurysm clipping may proceed. An occasional beat occurs even during circulatory arrest, which can be a problem if continued cardiac ejection causes significant vascular movement in the operative field. After the aneurysm is secured, CPB is slowly reestablished and extracorporeal blood flows and systemic cardiovascular pressures are monitored to test the repair and assess hemostasis. If further periods of circulatory arrest are deemed necessary, hypothermic flow can be reinstated until the systemic venous oxygen saturation returns to near the prearrest level. Based on theoretical and practical considerations,¹⁶ 45 min is thought to be a safe upper limit of total arrest time, but shorter periods are usually used. When the neurosurgeon believes optimal clip placement has been achieved, CPB is resumed and rewarming commences.

Nitroprusside (with or without some use of potent volatile anesthetic agents) may be used to control arterial vascular resistance and arterial blood pressure. Spontaneous cardiac rhythm usually reappears between 20 and 26°C. If present, ventricular fibrillation may be electrically cardioverted. In patients without any cardiac comorbidity, inotropes are rarely needed to wean the patient from CPB. After separation from CPB, heparin is reversed with protamine (0.75 mg protamine per 100 U heparin initially administered). Initial post-CPB hematocrit, platelet count, and coagulation studies (e.g., PT, aPTT, fibrinogen, *etc.*) are obtained to guide further therapy for disturbances of hemostasis after cardiopulmonary bypass. Autologous blood removed before CPB may be returned to the patient and the pump perfusate is concentrated and administered. An additional ACT is measured to confirm complete heparin reversal (ACT < 150 or within 10% of baseline value). Additional protamine is administered, if necessary, to counteract remaining heparin effect. Based on the clinical context, blood products are administered to correct any coagulopathies.

The patient is transported to the intensive care unit with cardiovascular monitoring and remains intubated and mechanically ventilated until return of adequate sensorium, ventilatory parameters, and muscle strength for extubation of the trachea. This might be within 3 or 4 h if propofol is used to induce and maintain EEG burst-suppression; a longer period of ventilatory support might be anticipated with use of thiopental or other barbiturates.

Discussion

There are many possible permutations on the above intraoperative protocol. If the goals of the various stages are met, the exact choice of agents or techniques to attain those goals is of secondary importance. There are a limited number of small series upon which to base recommendations.

Choice of Monitoring

In addition to pulmonary artery catheter, TEE monitoring may be useful in closed chest bypass methods. Transesophageal echocardiography allows (1) for assessment of ventricular volume and contractility (short-axis view at the papillary muscle level), (2) verification of the proper position of bypass cannulae (longitudinal view of the atria and cavae), and (3) monitoring of left and right ventricular distension during bypass (short-axis view at the papillary muscle level or four-chamber view). However, the advantages of additional information must be weighed against the risks of TEE monitoring, which include pressure necrosis of the tongue or soft tissues, esophageal injury, or cervical spine injury with head flexion. Access to the TEE probe for intraoperative manipulation should be carefully considered when positioning the patient. A reasonably accessible "tunnel" can be fashioned with the drapes and various attachments to the operating table to make for intraoperative manipulation of the TEE probe possible.

Patients who have undergone recent SAH may be volume contracted, as a result of the disease process¹⁷ or recent osmotic diuresis used to treat elevated intracranial pressure or from contrast agents used during neuroimaging. Central venous access is desirable for both drug and pressure monitoring, and the incremental morbidity of placing a pulmonary artery catheter, especially with the use of ultrasound guidance for internal jugular vein cannulation, should be minimal. Care should be taken to insure that the right atrium is used as the zero reference for central pressures, but that an appropriate correction factor is introduced for monitoring cerebral perfusion pressure, either because of head placement above or below the level of the heart. In determining arterial blood levels, central venous pressure should be taken into account to most adequately indicate distal cerebral perfusion. A detailed description of measuring cardiac *versus* cerebral pressures is discussed elsewhere.¹⁸

The electroencephalogram may also provide a means of titrating anesthetic agents to some physiologic end point such as some clinically discernible ratio of burst-suppression.¹⁵ It must be kept in mind however, that burst-suppression does not necessarily correspond to "maximally-protective" doses of agents. Evoked potentials may also be of some use in monitoring, especially with posterior fossa lesions.¹⁶

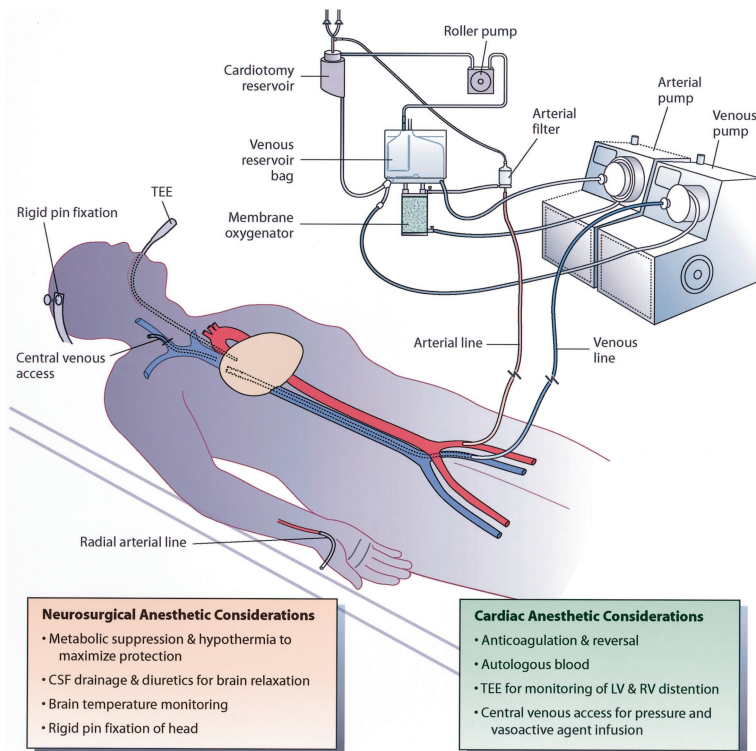


Fig. 1. Schematic view of closed-chest femoro-femoral cardiopulmonary bypass. A bypass circuit with two centrifugal pumps is used to augment venous drainage. Neurosurgical anesthetic considerations and cardiac anesthetic considerations are summarized. The drawing is conceptual and not meant to describe a functional bypass circuit.

CPB Methodology

There are several potential concerns with closed-chest femoro-femoral bypass. Myocardial protection relies on a reduction of myocardial oxygen consumption by affording hypothermia, empty ventricles, and asystole. Pharmacologic protection by cardioplegic solution is not available without aortic cross clamping. Assessing the adequacy of ventricular drainage is necessary, and this may be accomplished by monitoring central venous and pulmonary artery pressures or by direct visualization by TEE. Because of a lack of a left ventricular vent, overdistension of the left ventricle may require a conversion to open-chest bypass. Right ventricular overdistension often can be treated by augmenting venous drainage by increasing the height of an operative table relative to a venous reservoir. A bypass circuit with two centrifugal pumps or application of vacuum suction to the venous reservoir using a regulator may be used to increase venous drainage.¹⁹ Active venous return may facilitate reaching adequate bypass flow²⁰ (Fig. 1).

The effects of hypothermia, CPB, heparin, and protamine on hemostasis may result in significant postoperative bleeding. There are theoretical advantages of using heparin-bonded circuits that may allow lower systemic heparin doses and decrease the inflammatory effects of CPB. For a discussion of such topics (especially as they relate to cerebral dysfunction), as well as general considerations regarding hemostasis in bypass methodology, the reader is referred elsewhere.²¹

Spinal Catheters

Although not universally used by all aneurysm surgeons, indwelling lumbar spinal subarachnoid drainage is frequently used to achieve improved brain relaxation. Although patients are fully heparinized, we know of no problems with placement of spinal catheters. The lack of information about this topic is doubtlessly related to the fact that such catheter-related complications rarely occur, and we are discussing them in the context of an infrequently used procedure. This is presumably related to the fact that catheters are both placed and removed in a state of normal coagulation function, *i.e.*, the catheter is immobile during the period in which heparin is given and reversed with protamine. Nevertheless, vigilance for the rare complication of epidural or spinal hematoma is reasonable.

Conduct of Anesthesia

When setting goals for safe management of CPB and of cerebral aneurysm clipping we must consider the high incidence of cerebral injury during both of these procedures. Many patients who undergo these procedures have generally sound cardiovascular systems, making management of CPB relatively uncomplicated. The mechanisms of cerebral injury in this setting are similar to those seen when circulatory arrest is used for cardiac lesions, with some modification. The ability of deep hypothermia to afford protection from global cerebral hypoperfusion during circulatory arrest is well documented. In addition, there is also the possibility of focal cerebral ischemia from various embolic sources includ-

ing gas, blood products, and vascular wall debris. Deep hypothermia should protect against focal ischemia as well, but the time of maximal vulnerability for the occurrence of embolic focal injury may be before cooling and after rewarming—the time periods when thrombogenic cannula are being manipulated and systemic heparinization is being instituted or reversed.

In addition to the above general considerations, specific neurosurgical sources of focal brain injury may result from brain retraction and interruption of small end-arteries by dissection or clip placement. Furthermore, there may be areas of disturbed cerebral autoregulation if the patient has undergone a recent SAH, even if the patient is not overtly symptomatic. If such focal areas of cerebral ischemia exist, a particularly vulnerable period is during rewarming, for two reasons. First, inadvertent cerebral hyperthermia can happen during rewarming. Second, there seems to be an uncoupling of cerebral metabolic oxygen consumption and perfusion during the rewarming phase,²² which might adversely affect the brain already injured by SAH.

The interaction of the period of hypothermic arrest and brain regions previously damaged from a presenting SAH is unknown. Although most centers maintain relatively low mean arterial pressures during rewarming after routine CPB, it is probably reasonable to keep cerebral perfusion pressure within a patient's normal range ($\pm 10\%$) in the patient having experienced a recent SAH or with any preoperative evidence of vasospasm or ischemia.

Barbiturate, propofol, or volatile anesthetic has been suggested to afford some modicum of protection for potential areas of focal cerebral ischemia, both permanent (vessel interruption), and transient (retraction, hypotension).^{7,16 23-25} Unfortunately, there is no compelling evidence that they protect the brain in the setting of routine cardiopulmonary bypass,^{26,27} and no evidence at all that they are protective during neurosurgical procedures. Nevertheless, given the high morbidity of DHCA for aneurysm clipping and the relative safety of using thiopental, propofol, or volatile anesthetic, incorporating such agents into a part of the anesthetic maintenance plan may be reasonable.

Does Burst-Suppression Therapy Cause Adverse Cardiac Effects?

There is a common and appropriate concern that drugs used to induce EEG burst-suppression (barbiturates and propofol) may cause cardiac depression (we emphasize again that burst-suppression may not correspond to maximal protection, should protection even exist). That barbiturates seem not to cause cardiac dysfunction in the immediate post-CPB weaning period was documented by Stone *et al.*²⁴ Patients ($n = 24$) without significant cardiac disease underwent DHCA for aneurysm clipping using a fentanyl, nitrous oxide, and isoflu-

rane anesthetic. Thiopental was titrated to achieve EEG burst-suppression before CPB (as per the protocol cited previously), and the infusion was continued until after separation. Thiopental infusion continued for 2–3 h until after the bypass was terminated, and the overall infusion rate was $18 \pm 5 \text{ mg}\cdot\text{kg}^{-1}\cdot\text{h}^{-1}$. All patients were easily separated from bypass without inotropic support. Following bypass, there were minimal changes in vascular resistance (decreased), and heart rate, filling pressures, and cardiac index (increased); stroke volume had returned to its baseline; and ejection fraction was unchanged. Similar results have been reported by this same group in patients ($n = 13$) receiving propofol, with the added benefit of earlier emergence from anesthesia.²³ Nine of the 13 patients emerged from anesthesia and were able to follow commands at $3.1 \pm 1.4 \text{ h}$. Three others had strokes and a fourth had cerebral swelling.

Temperature Monitoring and Management

When profound hypothermia is rapidly induced and reversed, temperature measurements made at standard monitoring sites may not reflect cerebral temperature.²⁸ There appears to be no ideal site from which to monitor temperature in this setting of rapid temperature flux. Measurements from the nasopharynx, esophagus, and pulmonary artery tend to match brain temperature best (standard pulmonary artery catheters do not measure down to the temperature used during DHCA).²⁸ Using an array of temperature-measuring locations may make it easier to interpret conflicting or discordant readings.

It has been suggested that Nitroprusside accelerates rewarming. There is, however, no convincing evidence to support this contention for neurosurgical DHCA in doses that will maintain adequate cerebral perfusion pressure,²⁹ at least in comparison to volatile anesthetics such as isoflurane.³⁰

Unrecognized hyperthermia in patients admitted to the hospital is a major unresolved management problem.³¹ It is exceedingly common after all types of cerebral hemorrhage. Postbypass hyperthermia is common in cardiac surgery. For example, in one study of open chest for elective coronary or valve surgery, Yared *et al.*, found that, compared with placebo, patients receiving dexamethasone had a lower incidence of early postoperative fever (20% vs. 37%, $P = 0.009$).³² Since many patients will be receiving dexamethasone for their neurosurgical management, perhaps the lower figure is more applicable. The lower number notwithstanding, given current knowledge about the deleterious effects of hyperthermia on the outcome from cerebral ischemia,^{33,34} it is still an alarmingly high fraction. The combination of post-CPB and post-SAH febrile states makes it highly likely that patients undergoing DHCA will have an increase in their body temperature postoperatively. In light of the evidence linking hyperthermia with adverse

neurologic outcome, consideration of aggressive temperature control should be entertained.

Acid-base management, *i.e.*, pH-stat *versus* α -stat during CPB, remains a point of controversy.³⁵ In pediatric patients, pH-stat may hasten recovery of EEG activity.³⁶ Alpha-stat management may result in favorable cognitive function in adult patient after CPB.³⁷ During moderate hypothermic CPB, Murkin *et al.*, found no differences in outcome between pH-stat and α -stat strategies, except in patients who were on bypass for more than 90 min.³⁵ The relevance of these findings to neurosurgical application of DHCA is unclear.

On the theoretical level, relatively higher cerebral blood flow with pH-stat might facilitate faster cooling or warming of the brain. Conversely, higher flows and lower cerebral resistance may increase delivery of embolic material to the cerebral circulation. Relatively greater cerebral blood flow may also interfere with brain relaxation, or exacerbate decreased intracranial compliance with the cranium closed.

Outcome

A detailed review of outcome is beyond the scope of this review. However, one set of recently reported data from a highly experienced group will serve to make an important point— despite the ability of DHCA to afford definitive therapy to some patients, it is an exceedingly morbid procedure. Lawton *et al.* reported their experience with 60 patients treated with 62 DHCA procedures over a 12-yr period.⁹ Treatment complications occurred in 37% of patients and included postoperative intracranial hematoma (15%), some type of cerebral infarction (16%), and cranial nerve morbidity (55%, more than half of which was transient). Major medical complications included a fatal myocardial infarction, sepsis in 4 patients, and transfusion-related hepatitis in 1 patient. The operative mortality in these 60 patients was 8.3%. Delayed deaths related to treatment occurred in an additional 10%. Surgical morbidity included transient neurologic deterioration in 15% and permanent neurologic deterioration in 6.7%.

Summary and Conclusions

For the future, advances in less invasive methods of circulatory manipulation may one day further decrease the need to use deep hypothermic circulatory arrest. Such methods might include temporary cardiac pause^{38,39} and new developments in endovascular approaches such as aneurysm coiling and stenting. In the meantime, however, DHCA for cerebral aneurysm clipping may be offered to carefully selected patients harboring intracranial aneurysms at quaternary treatment centers. Even at such centers, experience is limited.

The authors thank the staff of the Center for Cerebrovascular Research, and Annemarie Thompson, M.D., for assistance in manuscript preparation. The se-

nior author gratefully acknowledges the contributions of his past and present colleagues at Columbia-Presbyterian Medical Center of New York, Presbyterian Hospital, New York, NY in the development of the clinical protocols; Linda B. Mongero, Chief Perfusionist, kindly provided material for Fig. 1.

References

- Solomon RA: Principles of aneurysm surgery: Cerebral ischemic protection, hypothermia, and circulatory arrest (review). *Clin Neurosurg* 1994; 41:351-63
- Young WL: Cerebral aneurysms: Current anaesthetic management and future horizons/Anévrismes cérébraux: Prise en charge anesthésique courante et horizons futurs (lecture). *Can J Anaesth* 1998; 45:R17-R24, R25-R31
- Johnston SC, Wilson CB, Halbach VV, Higashida RT, Dowd CF, McDermott MW, Applebury CB, Farley TL, Gress DR: Endovascular and surgical treatment of unruptured cerebral aneurysms: Comparison of risks. *Ann Neurol* 2000; 48:11-9
- Patterson RH, Ray BS: Profound hypothermia for intracranial surgery: Laboratory and clinical experiences with extracorporeal circulation by peripheral cannulation. *Ann Surg* 1962; 156:377-93
- Drake CG, Barr HWK, Coles JC, Gergely NF: The use of extracorporeal circulation and profound hypothermia in the treatment of ruptured intracranial aneurysm. *J Neurosurg* 1964; 21:575-81
- Rosenthal E: At surgery's frontier: Suspended animation. *New York Times* 1990; November 13:C-1 (col. 1), 12 (col. 3)
- Solomon RA, Smith C, Young WL, Stone JG, Fink M: Deep hypothermic circulatory arrest for the management of complex anterior and posterior circulation aneurysms (poster presentation 1016). 59th Annual Meeting of the American Association of Neurological Surgeons, New Orleans, LA, 1991
- Silverberg GD, Reitz BA, Ream AK: Hypothermia and cardiac arrest in the treatment of giant aneurysms of the cerebral circulation and hemangioblastoma of the medulla. *J Neurosurg* 1981; 55:337-46
- Lawton MT, Raudzens PA, Zabramski JM, Spetzler RF: Hypothermic circulatory arrest in neurovascular surgery: Evolving indications and predictors of patient outcome. *Neurosurgery* 1998; 43:10-20; discussion 20-1
- Connolly ES, Jr, Solomon RA: Hypothermic cardiac standstill for cerebral aneurysm surgery. *Neurosurg Clin N Am* 1998; 9:681-95
- Sahs AL, Perret GE, Locksley HB, Nishioka H, eds: *Intracranial Aneurysms and Subarachnoid Hemorrhage: A Cooperative Study*. Philadelphia, Lippincott, 1969:1-296
- Iwama T, Hashimoto N, Todaka T, Sasako Y, Inamori S, Kuro M: Resection of a large, high-flow arteriovenous malformation during hypotension and hypothermia induced by a percutaneous cardiopulmonary support system. *J Neurosurg* 1997; 87:440-44
- Barker FG, II, Ogilvy CS: Efficacy of prophylactic nimodipine for delayed ischemic deficit after subarachnoid hemorrhage: A metaanalysis. *J Neurosurg* 1996; 84:405-14
- Young WL, Pile-Spellman J: Anesthesia for interventional neuroradiology (review). *CO Anaesthesiology* 1994; 7:409-15
- Young WL, Solomon RA, Pedley TA, Ross L, Schwartz AE, Ornstein E, Matteo RS, Ostapkovich N: Direct cortical EEG monitoring during temporary vascular occlusion for cerebral aneurysm surgery. *ANESTHESIOLOGY* 1989; 71:794-9
- Spetzler RF, Hadley MN, Rigamonti D, Carter LP, Raudzens PA, Shedd SA, Wilkinson E: Aneurysms of the basilar artery treated with circulatory arrest, hypothermia, and barbiturate cerebral protection. *J Neurosurg* 1988; 68:868-79
- Solomon RA, Post KD, McMurtry JG III: Depression of circulating blood volume in patients after subarachnoid hemorrhage: Implications for the management of symptomatic vasospasm. *Neurosurgery* 1984; 15:354-61
- Young WL, Kader A, Pile-Spellman J, Ornstein E, Stein BM, Columbia University AVM Study Project: Arteriovenous malformation draining vein physiology and determinants of transdural pressure gradients. *Neurosurgery* 1994; 35:389-95, discussion 395-6
- Aebert H, Brawanski A, Philipp A, Behr R, Ullrich OW, Keyl C, Birnbaum DE: Deep hypothermia and circulatory arrest for surgery of complex intracranial aneurysms. *Eur J Cardiothorac Surg* 1998; 13:223-9
- MacDonald JL, Cleland AG, Mayer RL, Henderson MJ: Extracorporeal circuit design considerations for giant intracranial aneurysm repair. *Perfusion* 1997; 12:193-6
- Murkin JM: Etiology and incidence of brain dysfunction after cardiac surgery. *J Cardiothorac Vasc Anesth* 1999; 13:12-7, discussion 36-7
- Enomoto S, Hindman BJ, Dexter F, Snith T, Cutkomp J: Rapid rewarming causes an increase in the cerebral metabolic rate for oxygen that is temporarily unmatched by cerebral blood flow: A study during cardiopulmonary bypass in rabbits. *ANESTHESIOLOGY* 1996; 84:1392-400
- Stone JG, Young WL, Marans ZS, Solomon RA, Smith CR, Jamdar SC, Ostapkovich N, Diaz J: Consequences of electroencephalographic-suppressive doses of propofol in conjunction with deep hypothermic circulatory arrest. *ANESTHESIOLOGY* 1996; 85:497-501
- Stone JG, Young WL, Marans ZS, Khambatta HJ, Solomon RA, Smith CR, Ostapkovich N, Jamdar SC, Diaz J: Cardiac performance preserved despite thiopental loading. *ANESTHESIOLOGY* 1993; 79:36-41
- Warner DS, Zhou J, Ramani R, Todd MM: Reversible focal ischemia in the rat: Effects of halothane, isoflurane, and methohexital anesthesia. *J Cereb Blood Flow Metab* 1991; 11:794-802

26. Zaidan JR, Klochany A, Martin WM, Ziegler JS, Harless DM, Andrews RB: Effect of thiopental on neurologic outcome following coronary artery bypass grafting. *ANESTHESIOLOGY* 1991; 74:406-11
27. Roach GW, Newman MF, Murkin JM, Martzke J, Ruskin A, Li J, Guo A, Wisniewski A, Mangano DT: Ineffectiveness of burst suppression therapy in mitigating perioperative cerebrovascular dysfunction: Multicenter Study of Perioperative Ischemia (McSPI) Research Group (see comments). *ANESTHESIOLOGY* 1999; 90:1255-64
28. Stone JG, Young WL, Smith CR, Solomon RA, Wald A, Ostapkovich N, Shrebnick DB: Do standard monitoring sites reflect true brain temperature when profound hypothermia is rapidly induced and reversed? *ANESTHESIOLOGY* 1995; 82:344-51
29. Rajek A, Lenhardt R, Sessler DI, Brunner G, Haisjackl M, Kastner J, Laufer G: Efficacy of two methods for reducing postbypass afterdrop. *ANESTHESIOLOGY* 2000; 92:447-56
30. Tugrul M, Pembeci K, Camci E, Ozkan T, Telci L: Comparison of the effects of sodium nitroprusside and isoflurane during rewarming on cardiopulmonary bypass. *J Cardiothorac Vasc Anesth* 1997; 11:712-7
31. Albrecht RF II, Wass CT, Lanier WL: Occurrence of potentially detrimental temperature alterations in hospitalized patients at risk for brain injury. *Mayo Clin Proc* 1998; 73:629-35
32. Yared JP, Starr NJ, Torres FK, Bashour CA, Bourdakos G, Piedmonte M, Michener JA, Davis JA, Rosenberger TE: Effects of single dose, postinduction dexamethasone on recovery after cardiac surgery. *Ann Thorac Surg* 2000; 69:1420-4
33. Warner DS, McFarlane C, Todd MM, Ludwig P, McAllister AM: Sevoflurane and halothane reduce focal ischemic brain damage in the rat: Possible influence on thermoregulation. *ANESTHESIOLOGY* 1993; 79:985-92
34. Wass CT, Lanier WL, Hofer RE, Scheithauer BW, Andrew AG: Temperature changes of $\geq 1^\circ\text{C}$ alter functional neurologic outcome and histopathology in a canine model of complete cerebral ischemia. *ANESTHESIOLOGY* 1995; 83:325-35
35. Murkin JM, Martzke JS, Buchan AM, Bentley C, Wong CJ: A randomized study of the influence of perfusion technique and pH management strategy in 316 patients undergoing coronary artery bypass surgery, II: Neurologic and cognitive outcomes. *J Thorac Cardiovasc Surg* 1995; 110:349-62
36. du Plessis AJ, Jonas RA, Wypij D, Hickey PR, Riviello J, Wessel DL, Roth SJ, Burrows FA, Walter G, Farrell DM, Walsh AZ, Plumb CA, del Nido P, Burke RP, Castaneda AR, Mayer JE, Jr, Newburger JW: Perioperative effects of alpha-stat versus pH-stat strategies for deep hypothermic cardiopulmonary bypass in infants. *J Thorac Cardiovasc Surg* 1997; 114:991-1000, discussion 1000-1
37. Venn GE, Patel RL, Chambers DJ: Cardiopulmonary bypass: Perioperative cerebral blood flow and postoperative cognitive deficit. *Ann Thorac Surg* 1995; 59:1331-5
38. Kahn RA, Marin ML, Hollier L, Parsons R, Griep R: Induction of ventricular fibrillation to facilitate endovascular stent graft repair of thoracic aortic aneurysms. *ANESTHESIOLOGY* 1998; 88:534-6
39. Hashimoto T, Young WL, Aagaard BD, Joshi S, Ostapkovich ND, Pile-Spellman J: Adenosine-induced ventricular asystole to induce transient profound systemic hypotension in patients undergoing endovascular therapy. Dose-response characteristics. *ANESTHESIOLOGY* 2000; 93:998-1001